

Case Study: Autoimmune Hepatitis and Pancytopenia in Pregnancy

Zenobia Gonsalves, MD; Rachel Lee, MD; Sophia Wang, MD; Ayesha Hussain, DO; Kimberly Herrera, MD

Background

- Autoimmune hepatitis (AIH) is a chronic inflammatory disease of unknown etiology characterized by progressive hepatocellular inflammation and necrosis that may progress to cirrhosis.
- Treatment goals include improving symptoms, reducing liver inflammation, and preventing disease progression.^{1,2} This starts with glucocorticoid treatment, with azathioprine as maintenance.
- Overall prognosis is high, with 10-year survival rates of 90%,³ however cirrhosis is associated with higher mortality rates.⁴

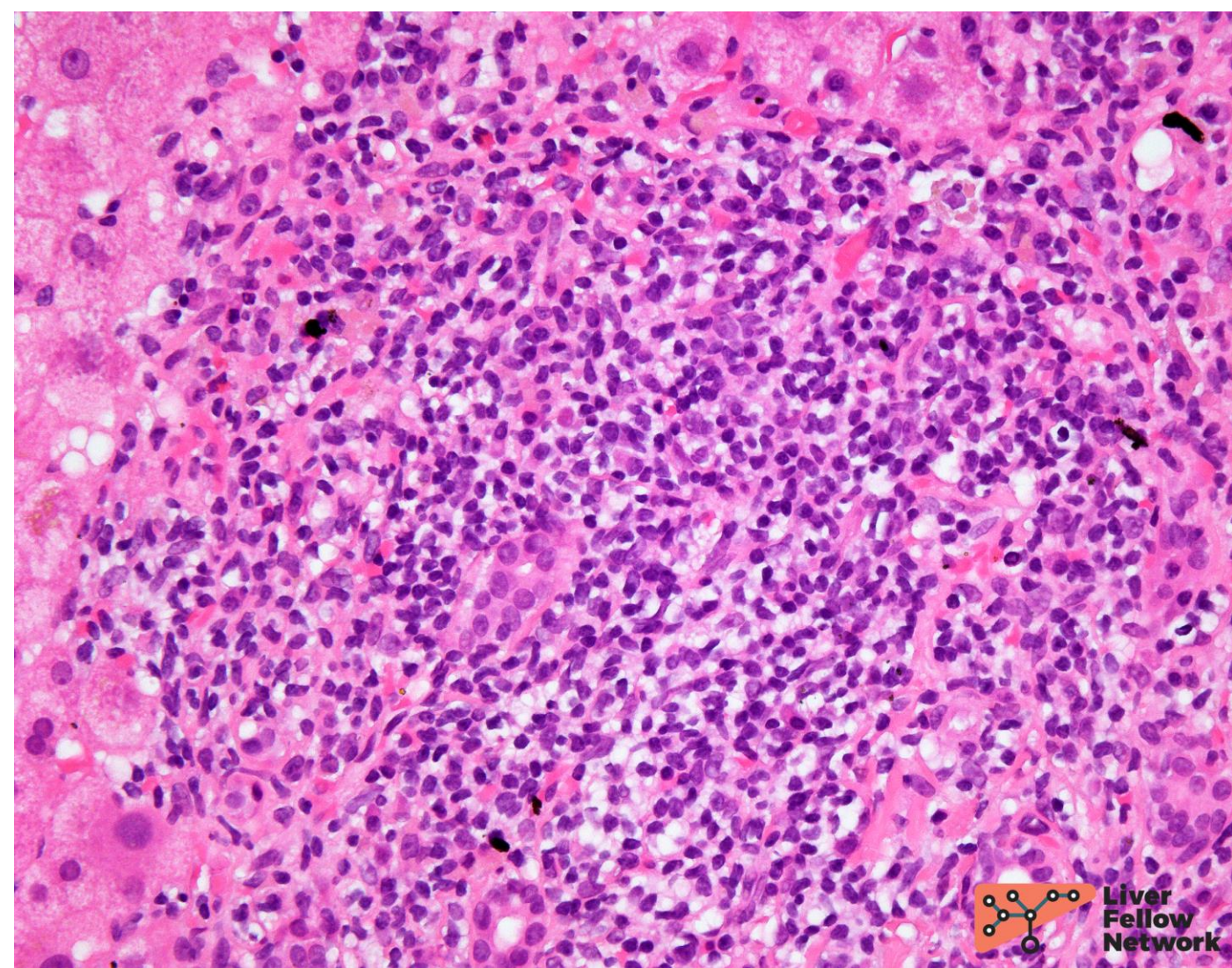


Figure 1: Liver biopsy of autoimmune hepatitis (AIH) showing portal inflammation, composed of lymphocytes, scattered plasma cells, and rare eosinophils. Pathology Pearls Post 6: Autoimmune Hepatitis. Bell, Phoenix. Figure on AASLD. Available from: <https://www.aasld.org/liver-fellow-network/core-series/pathology-pearls/pathology-pearls-post-6-autoimmune-hepatitis-aih> [Accessed 12 Oct, 2023]

- AIH disproportionately affects reproductive-aged females. AIH in pregnancy is associated with many adverse maternal and fetal outcomes.^{5,6}

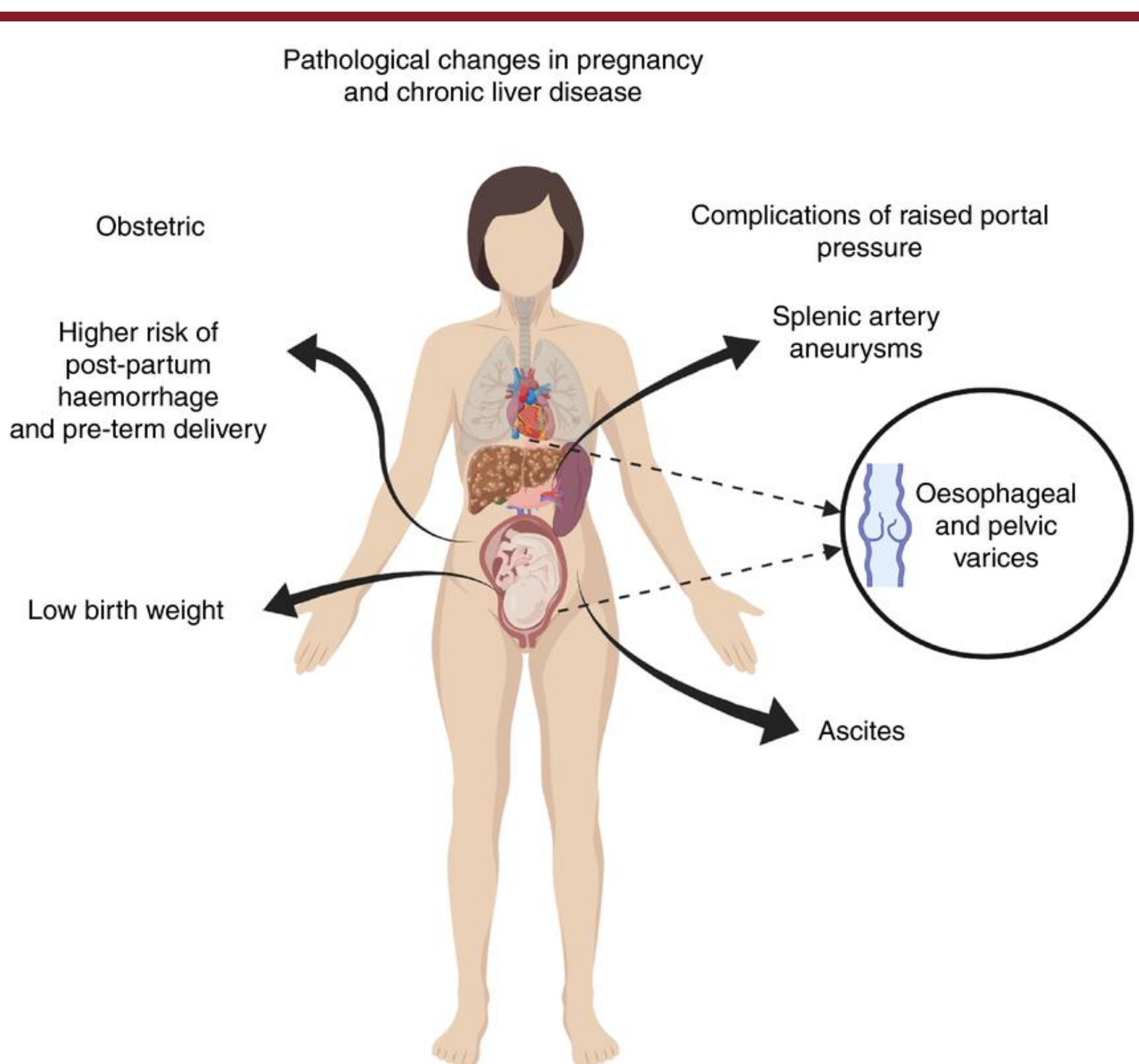


Figure 2: Review article: chronic liver disease and pregnancy - Scientific Figure on ResearchGate. Available from: https://www.researchgate.net/figure/Pathological-changes-in-pregnancy-and-chronic-liver-disease-Created-withBioRendercom_fig2_342534364 [Accessed 12 Oct, 2023]

Case Presentation

Presenting Illness and Past Medical History

- A 29-year-old G4P0121 female presented to prenatal care at 7 weeks gestation with diagnosis of AIH with cirrhosis. The patient was incidentally found to be pregnant during workup of new-onset pancytopenia.
- She had a history of spontaneous preterm delivery at 36 weeks complicated by cirrhosis, sepsis, thrombocytopenia, acute kidney injury, and spontaneous bacterial peritonitis (SBP).

Pregnancy Course

- The current pregnancy was co-managed by Maternal Fetal Medicine, Gastroenterology, and Hematology.
- The patient was maintained on azathioprine, prednisone, and trimethoprim/sulfamethoxazole throughout pregnancy.
- She developed mild pulmonary hypertension suspected due to right heart disease from AIH.
- Between 31 and 32 weeks, she was hospitalized multiple times for management of steroid-unresponsive pancytopenia of unclear etiology with severe Coombs-negative anemia unresponsive to packed red blood cell transfusion. She had received 19U PRBC in transfusions since her pregnancy started. (See admission labs on right.)

WBC	1.60
RBC	2.05
Hemoglobin	6.4
Hematocrit	18.1
MCV	88.3
MCH	31.2
RDW	19.9
Platelet	56
Anisocytosis	2+
Basophilic stippling	1+
Elliptocytes	1+
Microcytosis	2+
Ovalocytes	1+
Poikilocytosis	2+
Spherocytes	1+
Reticulocyte count	3.19%
Fibrinogen	216
ALT/AST	11/24
BUN/Cr	0/0.54
Albumin	2.4

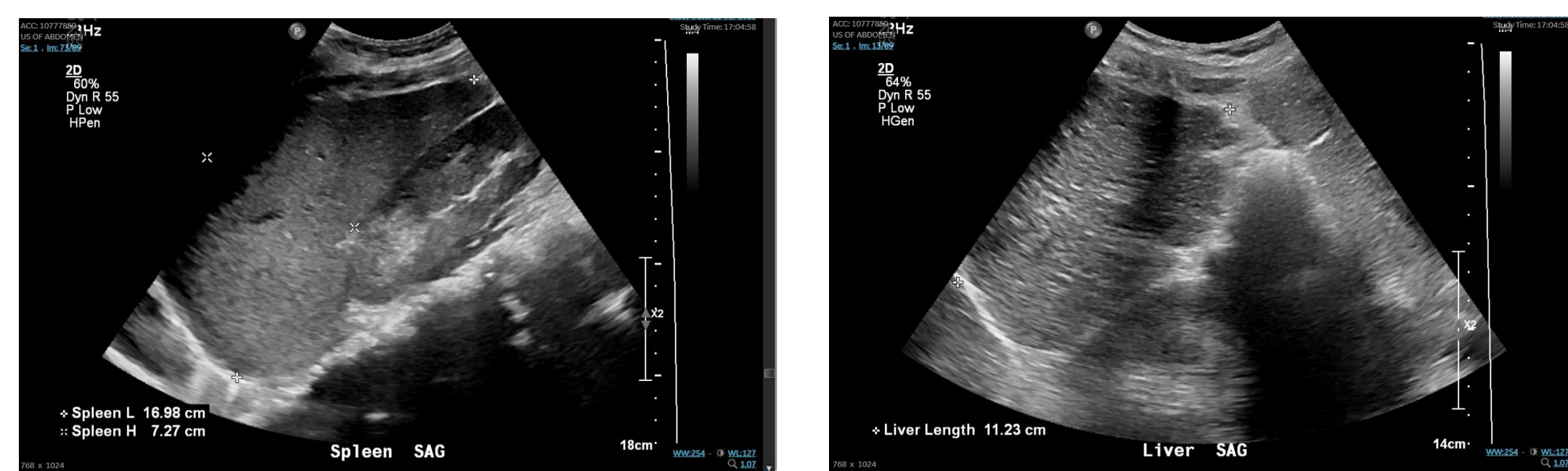
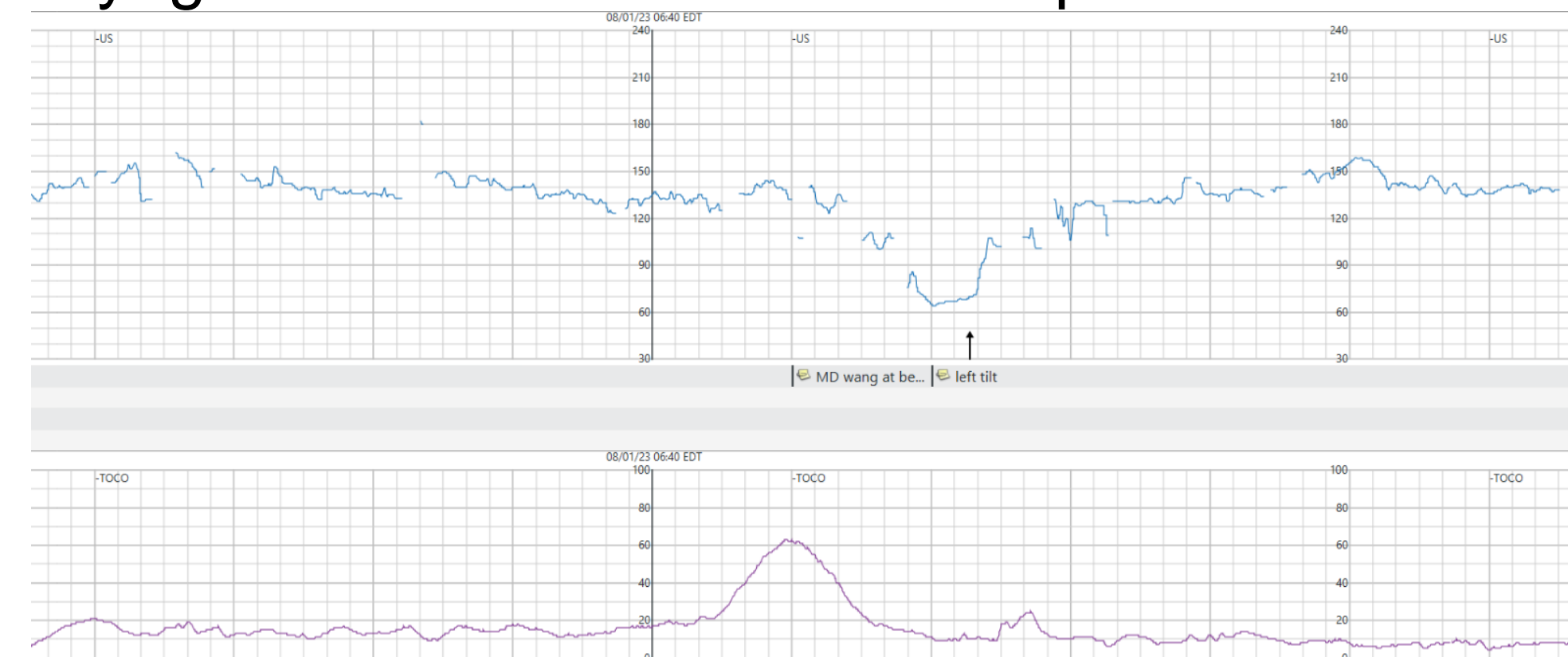


Figure 3: Abdominal ultrasound demonstrated known cirrhosis, splenomegaly

Delivery Decision

- At 33 weeks, decision was made for delivery via cesarean section due to persistent Category II fetal heart tracing with fetal breech presentation.
- For preoperative optimization, the patient was transfused 1U platelet, 4U packed red blood cells, albumin, and cryoglobulin with additional blood products on call to the operating room.



Postpartum Complications

- Delivery was complicated by hemorrhage with estimated blood loss of 1L, requiring multiple blood products (3U PRBC, 4U FFP, 1U platelet) as well as tranexamic acid.
- Postpartum course was complicated by sepsis secondary to urinary tract infection, and decompensated cirrhosis with hepatic encephalopathy and coagulopathy.

Conclusion

- This case highlights the challenges in management of AIH in pregnancy, particularly the difficulty in balancing the need for immunosuppression with the increased risk of infection that may lead to sequelae such as spontaneous bacterial peritonitis and sepsis.
- The clinical presentation of AIH can be complex, and demonstrates the need for a multidisciplinary team in the care of patients who have complications.

Citations

- Diagnosis and Management of Autoimmune Hepatitis in Adults and Children: 2019 Practice Guidance and Guidelines From the American Association for the Study of Liver Diseases. Mack CL, Adams D, Assis DN, Kerkar N, Manns MP, Mayo MJ, Vierling JM, Alsawas M, Murad MH, Czaja AJ. Hepatology. 2020;72(2):671. Epub 2020 May 12.
- Systematic review of response criteria and endpoints in autoimmune hepatitis by the International Autoimmune Hepatitis Group. Pape S, Sniijders RJALM, Gevers TJG, Chazouilleres O, Dalekos GN, Hirschfield GM, Lenzi M, Trauner M, Manns MP, Vierling JM, Montano-Loza AJ, Lohse AW, Schramm C, Drenth JPH, Heneghan MA, International Autoimmune Hepatitis Group (IAIHG) collaborators(†) J Hepatol. 2022;76(4):841. Epub 2022 Jan 20.
- Autoimmune hepatitis: a review. Gossard AA, Lindor KD. J Gastroenterol. 2012 May;47(5):498-503. Epub 2012 Apr 17.
- Autoimmune hepatitis: effect of symptoms and cirrhosis on natural history and outcome. Feld JJ, Dinh H, Arenovich T, Marcus VA, Wanless IR, Heathcote EJ. Hepatology. 2005;42(1):53.
- Pregnancy in autoimmune hepatitis: outcome and risk factors. Schramm C, Herkel J, Beuers U, Kanzler S, Galle PR, Lohse AW. Am J Gastroenterol. 2006;101(3):556. Epub 2006 Feb 8.
- Management and outcome of pregnancy in autoimmune hepatitis. Heneghan MA, Norris SM, O'Grady JG, Harrison PM, McFarlane IG. Gut. 2001;48(1):97.

Acknowledgements

Acknowledgements to Stony Brook University Hospital department of Maternal Fetal Medicine, Obstetric Anesthesia, Gastroenterology, and Hematology, as well as all nursing staff, who were active participants in the patient's care.